D.C. TRACTS

Spring 2019 Volume 31 Number 1

For info on upcoming issues and more, follow us on Twitter @DCTRACTS

Published by Data Trace Publishing Company
P.O. Box 1239, Brooklandville, MD 21022-9978
Order subscriptions toll free 800-342-0454 or fax 410-494-0515
www.datatrace.com/medical/chiropractic-publications.html

Welcome, Dr. Bryan Bond

D.C. Tracts would like to warmly welcome our new Editor-in-Chief, Dr. Bryan Bond, who has been an avid contributor over the years.

Dr. Bond received his BS in Kinesiology from the University of Waterloo in Ontario, and his BS in Human Biology and Doctor of Chiropractic degrees from the National University of Health Sciences. He has a master's degree in Biomechanics from the University of Kansas and a PhD in Rehabilitation Science from the University of Kansas Medical Center.

He spent several years in private practice before joining Cleveland Chiropractic College in 2002. After ten years teaching at CCC, he accepted a full-time faculty position at the University of Saint Mary in Leavenworth, Kansas. He is currently a Professor of Biomechanics, Human Imaging and Musculoskeletal Assessment at USM and Co-Director of Research in the Department of Physical Therapy. He has presented post-graduate workshops for a number of state and national professional associations.

Dr. Bond's experience will bring valuable insight to our publication, and we are excited to welcome him to the team.

TEMPOROMANDIBULAR JOINT DYSFUNCTION

COMING UP IN THE NEXT ISSUE

D.C. Tracts Volume 31, Number 2 will highlight the thoracic spine. Lectures will be presented by Dr. Adam Yoder on evidence-based treatment for thoracic spine pain and Dr. Patrick Battaglia on differential diagnosis and evaluation of thoracic spine pain. Dr. Bryan Bond will present the feature article on the impact of thoracic spine pain on overall health.

LETTER FROM THE EDITOR-IN-CHIEF

This issue of *D.C. Tracts* is a thorough, insightful review of temporomandibular disorders (TMDs) related to their structural, functional, psychosocial and clinical characteristics. Considering TMD's relatively high prevalence and significant financial burden, a comprehensive discussion of the clinical effects and conservative management is important.

In his lecture, Dr. Justin Hildebrand provides a brief overview of the anatomical and biomechanical considerations of TMD, as well as the clinical presentation and examination of the issue. He also shares some clinical insight for conservative management including modalities, soft-tissue massage and dry needling.

Dr. Christopher Kinslow lectures on the clinical relevance of TMD and the substantial cost of management. He further highlights the psychosocial factors associated with TMD such as stress, anxiety and depression, emphasizing the role of chiropractors in identifying risk factors and appropriately referring for co-management. Finally, he outlines the role of chiropractors in managing TMD through patient education, lifestyle recommendations and patient reassurance.

Dr. Bradley Muir's feature article delivers an in-depth review of the anatomy and biomechanics of the temporomandibular joint. He outlines the functional and structural importance of the joint capsule, musculature, articular disc and ligaments, and conveys the importance of variations in normal resting jaw position.

I trust that you will find this issue of *D.C. Tracts* both informative and interesting, refining your clinical expertise and patient services.

Best regards,

Bryan M. Bond, BSc, BS, DC, MS, PhD
Editor-in-Chief

FEATURE ARTICLE

Temporomandibular Joint: A Review of the Anatomy and Biomechanics

Bradley J. Muir, HBSc (Kin), DC, FRCCSS(C)

Dr. Brad Muir graduated from the University of Waterloo in 1992 with an Honors Bachelor of Science degree in Kinesiology. During his seven years working as a kinesiologist, he also attained a diploma in acupuncture. Dr. Muir graduated from the Canadian Memorial Chiropractic College in 2003, and continued on at the chiropractic college to complete his Sports Sciences Residency, attaining his Sports Specialist Designation in 2006.

Dr. Muir is currently an Associate Professor at the Canadian Memorial Chiropractic College, where he is a supervising clinician in the Clinical Education Department. He also maintains a private practice in Pickering and Ajax, Ontario. Dr. Muir has lectured across Canada on a variety of topics and has published several peer-reviewed articles on sports and other related areas. He is the former Second Vice President on the Board of Directors of the Royal College of Chiropractic Sports Sciences.

D.C. Tracts. Copyright © 2019 Data Trace Publishing Company
Vol. 31, No. 1. Printed in U.S.A.
1041-469X/$8.00/19

INTRODUCTION

Temporomandibular disorders (TMDs) can be classified in a number of different ways. The National Institute of Dental and Craniofacial Research (NIDCR), a branch of the National Institutes of Health (NIH), classifies TMDs into three main categories: myofascial or muscular pain, internal derangement (which includes a dislocated jaw and problems with the articular disc located in the joint itself) and degenerative joint disease (which includes osteo and rheumatoid arthritis, amongst others).[1] It has been estimated that up to 50% of TMDs are related to myofascial problems of the jaw.[2]

The prevalence of TMD is reported to be 10 to 30%[3,4] in the general population, but may be as high as 42.9% in university students.[5] Females are twice as likely to suffer from TMD, but are five times more likely to seek care.[1] TMD can also have devastating health effects on those people who opt not to receive dental care because it can result in pain when opening the mouth or eating solid food.

The following is a review of the relevant anatomy of the temporomandibular joint (TMJ) and the tissues that affect its functioning, as well as a review of the normal biomechanics of the joint. A solid foundation in the anatomy and biomechanics of the TMJ is essential in understanding TMD and its subsequent treatment.

ANATOMY

Bones

The temporomandibular joint is the point at which the mandibular condyles articulate with the cranium, specifically the mandibular

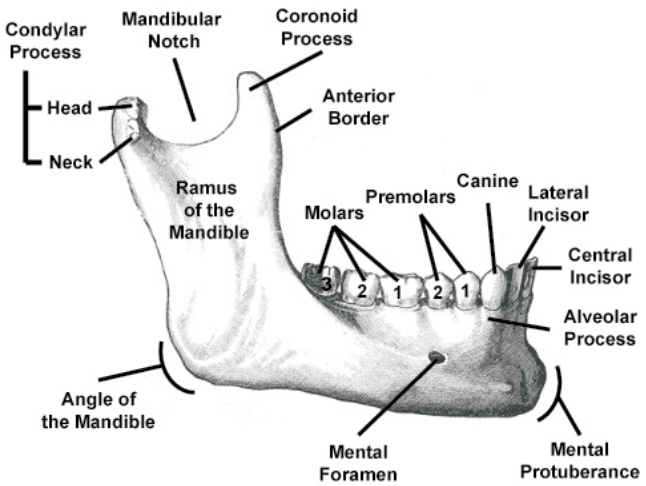

Figure 1. From: Gray's Anatomy of the Human Body, Twentieth Edition. Philadelphia, PA: Lea & Febiger; 1918.

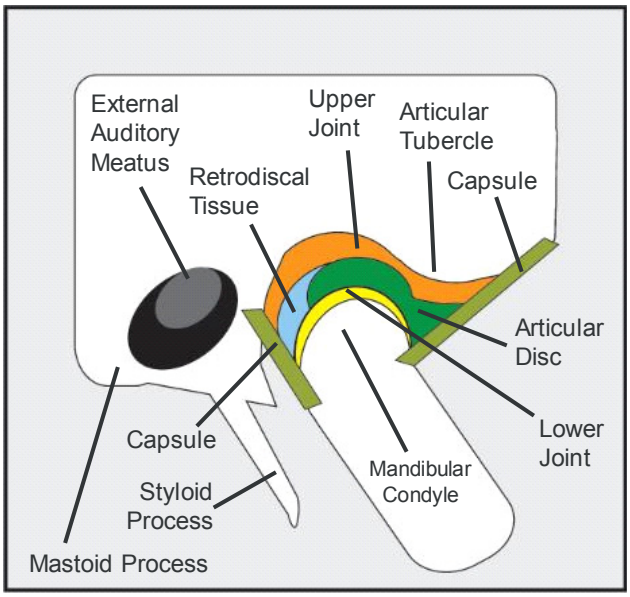

Figure 2. The upper and lower joint of the temporomandibular joint

(or glenoid) fossa of the squamous portion of the temporal bones.[6] The TMJ is unique in that both articulations must work together in order to function properly.[6] Another unique feature is that both bony surfaces are covered in fibrocartilage, while most synovial joint surfaces of the body are covered with hyaline cartilage.[6]

The mandible forms the lower aspect of the jaw and the face and is both the largest and strongest bone in the face[7] (the various components of the mandible are outlined in **Figure 1**). The mandible contains the housing (inferior alveolar processes) for the lower teeth. The mandible also articulates with the maxillary bones of the face via the teeth during occlusion. The maxilla bone contains the housing (superior alveolar processes) of the upper teeth.

The mandible is connected muscularly to the hyoid bone (a U-shaped bone located anterior to the cervical spine, inferior to the anterior aspect of the mandible and superior to the thyroid cartilage). Some of the suprahyoid musculature connects directly from the hyoid to the mandible, assisting in the functioning of the jaw.

Temporomandibular Joint

The TMJ is a diarthrodial synovial joint. From a functional standpoint, it is also labelled a ginglimodiarthrodial joint. A ginglymoid joint is one that rotates (or hinges), and the arthrodial portion refers to a joint that translates (or glides).[8]

An articular disc separates the TMJ into two separate joint spaces: an upper and a lower joint, each with their own synovial lining. The upper joint (or discotemporal joint) is the larger of the two and is formed by the superior surface of the disc and the inferior surface of the temporal bone. The upper joint accommodates the gliding of the TMJ.

The lower joint (or discomandibular joint) is formed by the anterior-superior surface of the mandibular condyle and the inferior surface of the disc. The lower joint allows for rotation or hinging of the TMJ. (**See Figure 2**.)

The TMJ is supplied by all five branches of the auriculotemporal nerve which itself is a branch of the mandibular division of the trigeminal nerve (CNV3).[9] Davidson et al. found that in each of the joints they dissected, the auriculotemporal nerve innervated the lateral aspect of the TM capsule. Seventy-five percent of the specimens had a distinct branch from the masseteric nerve, a branch of the maxillary division of the trigeminal nerve (CNV2), innervating the anteromedial aspect of the capsule and, 33% of the cadavers had a small branch emerging from the pterygoid musculature, thought to be a branch of the lateral pterygoid or deep temporal nerve (both from CNV3), innervating the medial aspect of the capsule.[10] No mention of the facial nerve innervating the TM was made in their study.

A study done by Cuccia et al. found that, in general, the vascular supply to the joint seemed to come from the lateral and medial aspects of the head of the mandibular condyle.[11] They also report that the lateral and anterior regions of the joint were mostly supplied by the superficial temporal artery, the anterior region by the posterior deep temporal artery, and the medial aspect by the anterior tympanic and middle meningeal arteries.[11]

Articular Disc

The articular disc is bi-concave in shape and is comprised of a dense fibrocartilaginous tissue.[6] The disc is fused with the artic-

Vol. 31, No. 1. Printed in U.S.A.
1041-469X/$8.00/19

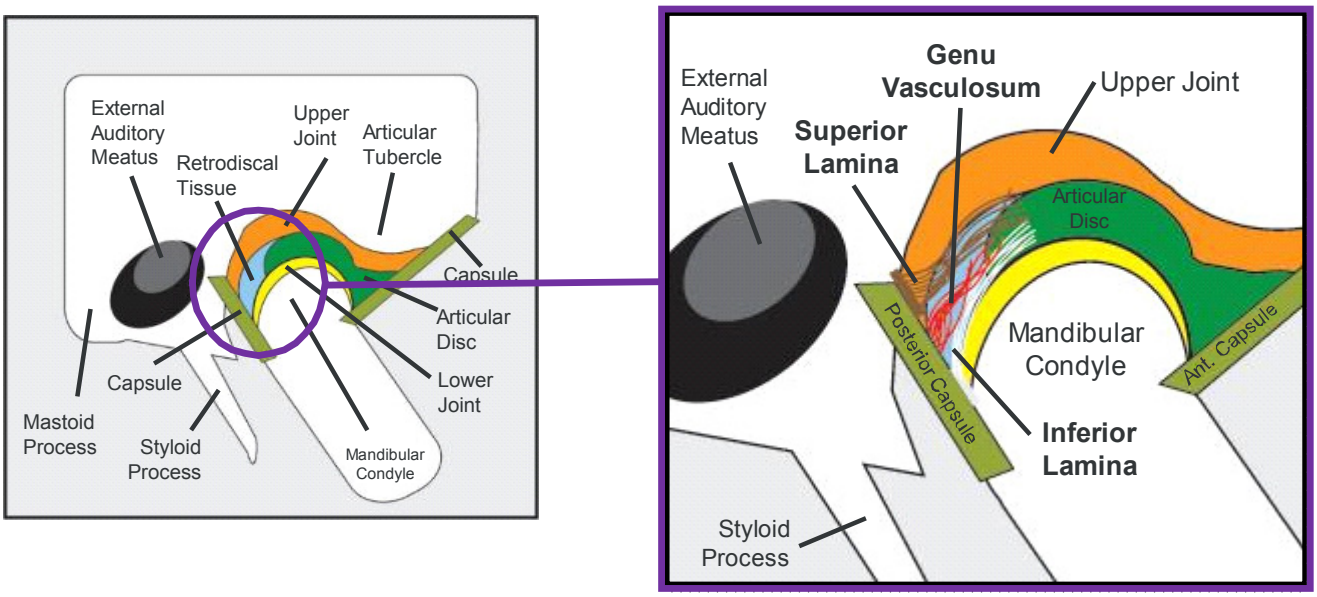

Figure 3. The retrodiscal tissue

ular capsule surrounding the joint, and through this connection is attached to the mandible and temporal bones.[12] The disc is more firmly attached to the mandible, allowing the disc and condyle to move as a unit.

Because the disc is comprised of fibrocartilage, it contains a much higher percentage of collagen which is suggested to increase both its stiffness and durability.[8] This is also suggested to increase its tensile strength and allow it to resist the long-term effects of pressure and friction.[7] The disc itself does not have any direct vascularization or innervation.[8,11]

Retrodiscal Tissue (Bilaminar Zone)

The posterior attachment of the disc (also known as the retrodiscal tissue, bilaminar zone and the retrodiscal pad) is both highly vascularized and highly innervated.[9] This zone contains two important ligaments or lamina (superior and inferior), loose connective tissue, fat and a synovial membrane.[9] (**See Figure 3**.)

The inferior lamina acts to keep the articular disc more firmly attached to the head of the mandibular condyle, which allows the condyle to rotate under the disc while preventing it from translating anteriorly.[9]

The area between the two lamina is called the genu vasculosum. As the name suggests, it is a highly vascularized area in the retrodiscal connective tissue.[9] Cuccia et al. reported that the posterior disc attachment region (retrodiscal tissue) was greatly vascularized, while the intermediate and anterior aspects of the disc were relatively devoid of vessels.[11]

D.C. Tracts. Copyright © 2019 Data Trace Publishing Company
Vol. 31, No. 1. Printed in U.S.A.
1041-469X/$8.00/19

Articular Capsule

The articular capsule of the TMJ attaches from the margins of the articular portion of the temporal bone down to the neck of the mandible. The anterior, medial and posterior part of the capsule is considered quite loose while the lateral capsule is taut and strong, due to the contribution of the temporomandibular (or lateral) ligament.[7] A synovial membrane lines the capsule.

Ligaments

According to Helland, there are three ligaments that are associated with the TMJ: the temporomandibular, sphenomandibular and stylomandibular ligaments.[7] The TM ligament is a fan-shaped ligament that has a broad superior attachment from the zygoma to a more narrow attachment on the mandibular neck. The TM ligament blends into the articular capsule and functions to restrain movements of the mandible, particularly into retrusion. It also acts to prevent compressive forces on the tissues posterior to the mandibular condyle. The sphenomandibular ligament attaches on the sphenoid bone at its spine to the lingula on the medial aspect of the mandibular ramus.[12] The stylomandibular ligament is a thickened band of the deep cervical fascia that attaches on the styloid process of the temporal bone running obliquely anterior and inferior to attach on the angle of the mandible.[12] In 1976, Shore suggested they function to keep the condyle, disc and temporal bone firmly opposed, while others feel the muscles fill this role sufficiently.[7]

MUSCULATURE

Muscles of Mastication

The muscles of mastication are those muscles that are involved in the chewing/grinding motion of the jaw. Four muscles are consid-

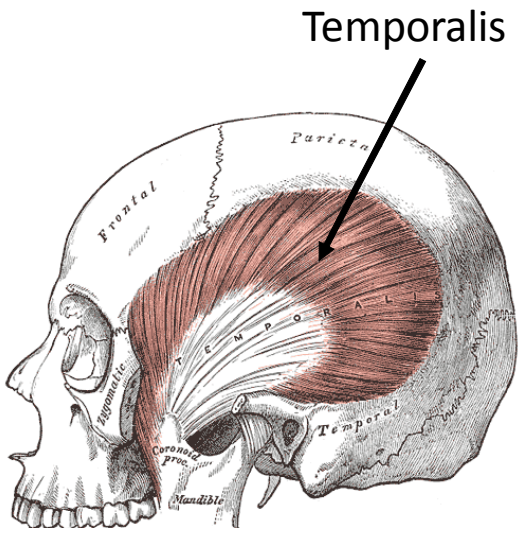

Figure 4. Muscles of mastication: Temporalis. From: Gray's Anatomy of the Human Body, Twentieth Edition. Philadelphia, PA: Lea & Febiger; 1918.

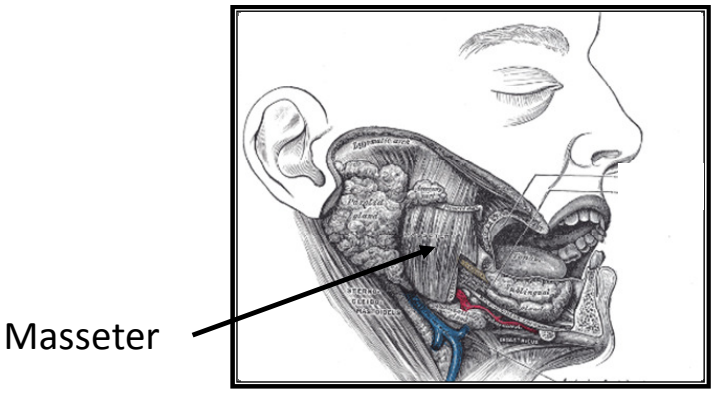

Figure 5. Muscles of mastication: Masseter. From: Gray's Anatomy of the Human Body, Twentieth Edition. Philadelphia, PA: Lea & Febiger; 1918

ered muscles of mastication: the temporalis, masseter and the medial and lateral pterygoid. Each of these muscles is innervated by the trigeminal nerve (CNV).

Temporalis: The temporalis muscle runs from the floor of the temporal fossa of the temporal bone and the temporal fascia to the coro noid process and the anterior border of the mandible. It acts to elevate the mandible (close the mouth) and its posterior fibers retract the mandible following protraction. It is innervated by the deep temporal branch of the mandibular nerve (CNV3).[12] (**See Figure 4**.)

Masseter: The masseter runs from the inferior margin and deep surface of the zygomatic arch to the lateral surface of the ramus and coronoid process of the mandible. It acts to elevate the mandible and clench the teeth, and aids in protracting the mandible. It is innervated by a branch of the mandibular nerve (CNV3) that enters its deep surface.[12] (**See Figure 5.**)

Medial Pterygoid: The medial pterygoid has two heads. The deep head attaches on the medial surface of the lateral pterygoid plate of the sphenoid bone while the superficial head attaches from the tuberosity of the maxilla. Both heads insert on the medial surface of the mandible near its angle. The medial pterygoid acts to assist in elevation and protraction of the mandible and is innervated by a branch of the mandibular nerve (CNV3). When acting alone, it pulls the chin away from the midline to the opposite side. When acting together, the bilateral medial pterygoids produce a grinding motion.[12] (**See Figure 6.**)

D.C. Tracts. Copyright © 2019 Data Trace Publishing Company
Vol. 31, No. 1. Printed in U.S.A.
1041-469X/$8.00/19

Lateral Pterygoid: The lateral pterygoid also has two heads. One head originates from the infratemporal surface of the greater wing of the sphenoid bone while the inferior head attaches on the lateral surface of the lateral pterygoid plate, also a part of the sphenoid bone. Both heads run to the neck of the mandible and articular disc of the TM joint. The lateral pterygoid will protrude and depress (open) the jaw when acting together, while they will produce side to side movement of the mandible when acting alone and alternately contracting. It is innervated by an anterior branch of the mandibular nerve (CNV3) that enters its deep surface.[12] (**See Figure 6.**)

Note: pterygoid means "wing-like," and with regard to human anatomy usually refers to the sphenoid bone of the cranium.

Suprahyoid Muscles

The suprahyoid muscles are those muscles that attach to the superior aspect of the hyoid bone and include the digastric, mylohyoid, geniohyoid and stylohyoid muscles. (**See Figure 7**.)

Digastric: The digastric has two bellies joined by a fibrous tendon at the hyoid bone. The anterior portion attaches at the digastric fossa which is the posterior aspect of the anterior mandible near the symphysis menti. The posterior belly of digastric arises from the mastoid notch on the medial side of the mastoid process, a conical prominence of the posterior temporal bone behind the ear. The anterior and posterior bellies join at a tendinous sling that is attached at the body and greater horn of the hyoid bone. It acts to raise the hyoid bone and stabilize it during swallowing and speaking when both bellies act together. With the hyoid stabilized, it can also pull posteriorly to open the mouth/depress the mandible. The anterior belly is innervated by the mylohyoid nerve, a branch of the inferior

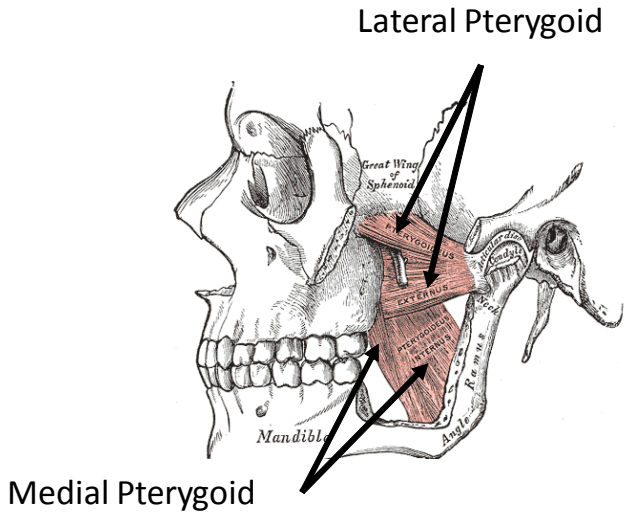

Figure 6. Muscles of mastication: Medial and lateral pterygoid. From: Gray's Anatomy of the Human Body, Twentieth Edition. Philadelphia, PA: Lea & Febiger; 1918.

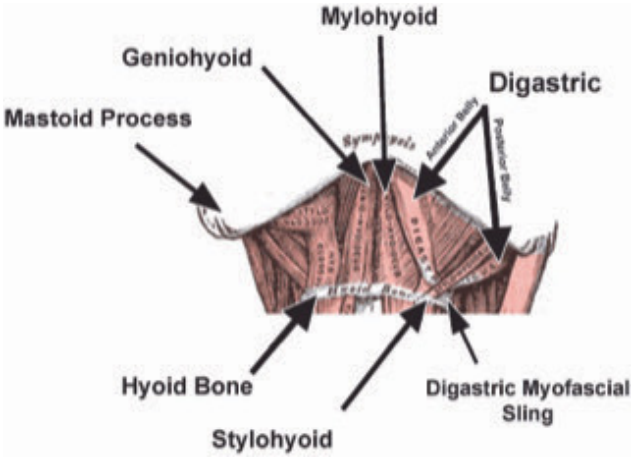

Figure 7. Suprahyoid muscles. From: Gray's Anatomy of the Human Body, Twentieth Edition. Philadelphia, PA: Lea & Febiger; 1918.

alveolar nerve (CNV3) while the posterior belly is innervated by the facial nerve (CN VII).[12]

Mylohyoid: The mylohyoid muscle attaches on the mylohyoid line on the medial aspect of the mandible and descends to attach inferiorly onto the raphe and body of the hyoid bone. It acts to elevate the hyoid, the floor of the mouth and the tongue in swallowing and speaking and is innervated by the mylohyoid nerve which is a branch of the inferior alveolar nerve (CNV3).[12]

Geniohyoid: The geniohyoid lies superior to the mylohyoid muscle and attaches superiorly to the inferior mental spine of the mandible and travels inferiorly to attach on the body of the hyoid bone. It acts to pull the hyoid anterior and superiorly to shorten the floor of the mouth and widen the pharynx during swallowing. It is innervated by the anterior ramus of the first cervical nerve via the hypoglossal nerve (CNXII).[12]

Stylohyoid: The stylohyoid attaches to the styloid process of the temporal bone. It runs almost parallel to the posterior belly of the digastric muscle to attach distally to the body of the hyoid bone. It acts to elevate and retract the hyoid bone which elongates the floor of the mouth during swallowing. It is innervated by the facial nerve (CN VII).[12]

D.C. Tracts. Copyright © 2019 Data Trace Publishing Company
Vol. 31, No. 1. Printed in U.S.A.
1041-469X/$8.00/19

Infrahyoid Muscles:

The infrahyoid muscles anchor the hyoid bone by attaching to its inferior aspect, and include the omohyoid, sternohyoid, sternothyroid and the thyrohyoid. The sternohyoid, sternothyroid and thyrohyoid have a limited effect on the functioning of the TM other than to stabilize the hyoid.

Omohyoid

The omohyoid has two bellies that are joined by an intermediate tendon that's connected to the clavicle by a fascial sling. The inferior belly of omohyoid attaches on the superior border of the scapula adjacent and medial to the suprascapular notch. It travels obliquely, anteriorly, and superiorly to its intermediate tendon. The superior belly arises from the intermediate tendon and travels superiorly to attach onto the inferior aspect of the hyoid. The omohyoid acts to depress, retract and stabilize the hyoid. It is innervated by C1 - C3 from the ansa cervicalis.[12] (**See Figure 8**.)

Variations in Normal Resting Jaw Position

There are several classes of malocclusion along with a multitude of dental, facial and cranial variations that can affect the TM and its range of motion. Two common variations that affect the maxilla and mandible include prognathism and retrognathism. Other common terms meant to define some of the changes in occlusion include overbite, underbite and overjet.

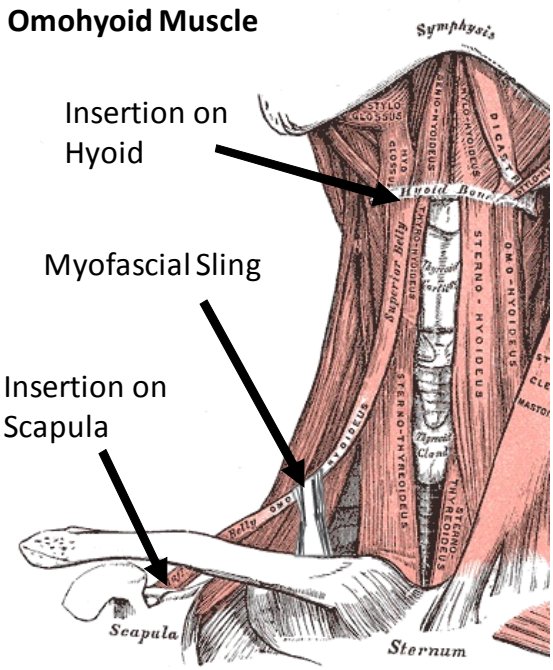

Figure 8. Omohyoid muscle. From: Gray's Anatomy of the Human Body, Twentieth Edition. Philadelphia, PA: Lea & Febiger; 1918.

Normal occlusion can be defined as occurring when "the mesiobuccal cusp of the maxillary first molar is aligned with the buccal groove of the mandibular first molar. There is alignment of the teeth, normal overbite, and overjet and coincident maxillary and mandibular midlines."[13]

Prognathism is from the Greek word "pro," meaning forward, and "gnathos" meaning jaw. It is defined as the "anterior protrusion of the mandibular alveolar ridge beyond the vertical plane of the maxillary alveolar ridge" and is subjective in its assessment.[14] Retrognathism is from the Greek word "retro" meaning backward, and is defined as a "posteriorly positioned lower jaw, which is set back from the plane of the face when viewed from the side but not from the front" and again is subjective in its assessment.[14] Both positions are defined relative to the "normal line of a 'normal' face" (an arbitrary line drawn to show relative the position of the face and jaw)[13] which is ill-defined in the literature.

Prognathism

Mandibular prognathism: Occurs when the mandible is located anterior to the "normal line of the face" and results in an underbite. The maxilla is considered to be normal.

Maxillary prognathism: Occurs when the maxilla is located anterior to the "normal line of the face" and results in an overjet and overbite. The mandible is considered to be normal.

Bimaxillary prognathism: Occurs when both the mandible and the maxilla are located anterior to the "normal line of the face."[13] (**See Figure 9**.)

Retrognathism

Mandibular retrognathism: Occurs when the mandible is located posterior to the "normal line of the face" and results in an overjet and overbite. The maxilla is considered normal. (**See Figure 10**.)

Maxillary Retrognathism: Occurs when the maxilla is located posterior to the "normal line of the face" and results in an underbite. The mandible is considered normal.

Bimaxillary Retrognathism: Occurs when both the mandible and maxilla are located posterior to the "normal line of the face."[13]

Overbite, Overjet and Underbite

Overbite refers to the vertical distance between the incisors of the maxilla over the incisors of the mandible, while overjet refers to the horizontal distance between the incisors of the maxilla ahead of the incisors of the mandible.[14] (**See Figure 11**.) An underbite occurs when the maxillary incisors are located posterior to the mandibular incisors.

BIOMECHANICS

Actions of the TMJ

The TMJ has the ability to perform several actions that can be broken down into combinations of specific movements that result in elevation (closing), depression (opening), protrusion, retrusion and lateral deviation.

Mandibular Depression (Opening)

Mandibular depression (opening) commences with contraction of the lateral pterygoid and suprahyoid muscles which combine to rotate the mandibular condyle in the lower portion of the joint (discomandibular joint). Of the suprahyoid musculature, the digastric, geniohyoid and the mylohyoid contribute the most to opening.[7]

Opening proceeds with the lateral pterygoid muscle pulling the condyle forward along the articular eminence in a motion described as translation or gliding.[7]

The superior segment of the lateral pterygoid muscle coordinates the rotation and translation of the articular disc with the mandibular condyle in order to keep the disc congruent with the condyle.[8]

Normal mandibular depression is usually reported as 40 to 60 mm. A study by Salaorni and Palla found that opening ranged from 43 to 72 mm, with mean opening being 55 mm (± 6 mm).[15] Another study done by Walker et al. reported a normal range of opening as 33 to 55 mm with a mean of 43.5 (± 6.1 mm).[16] (**See Figure 12**.)

Vol. 31, No. 1. Printed in U.S.A.
1041-469X/$8.00/19

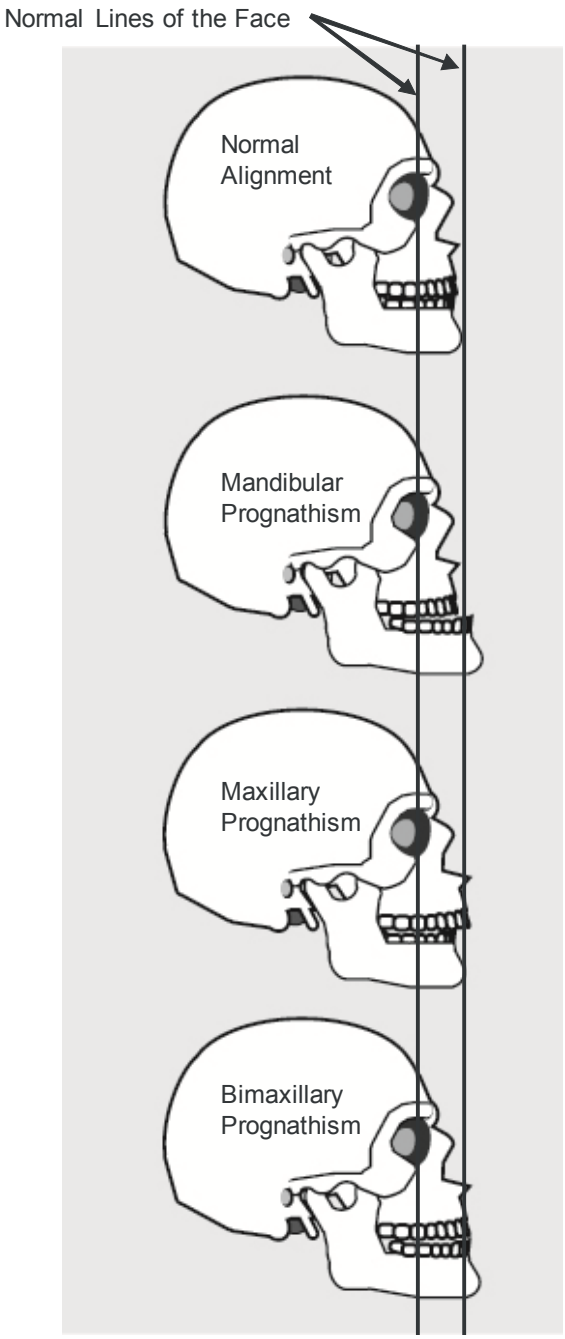

Figure 9. Prognathism

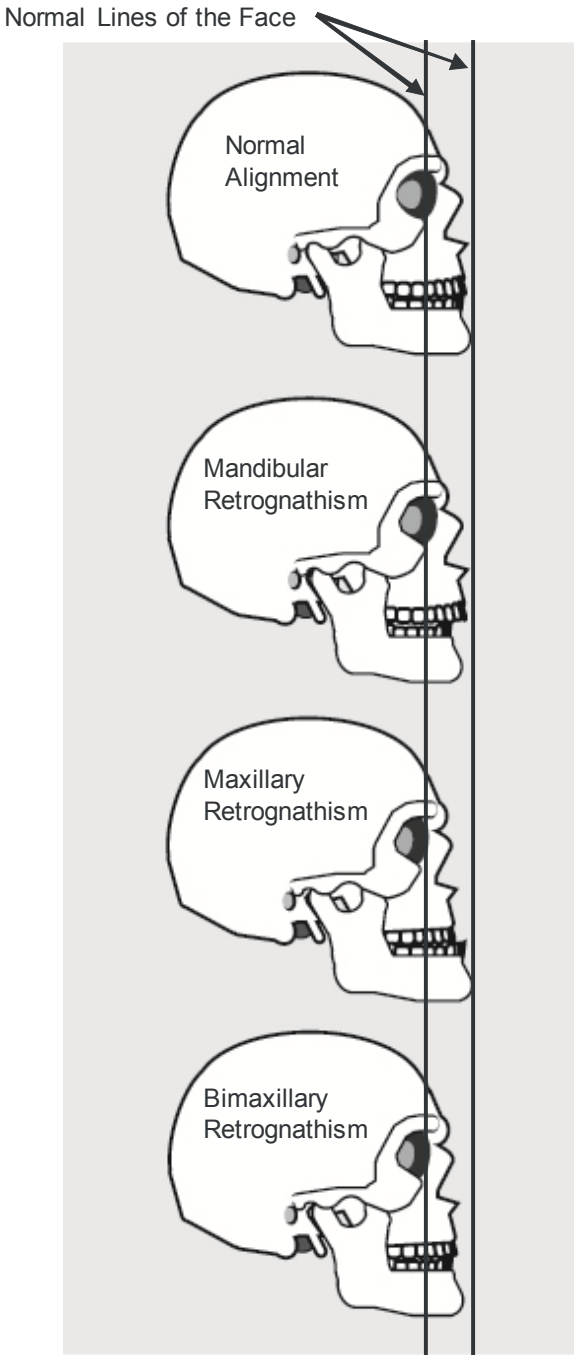

Figure 10. Retrognathism

Vol. 31, No. 1. Printed in U.S.A.
1041-469X/$8.00/19

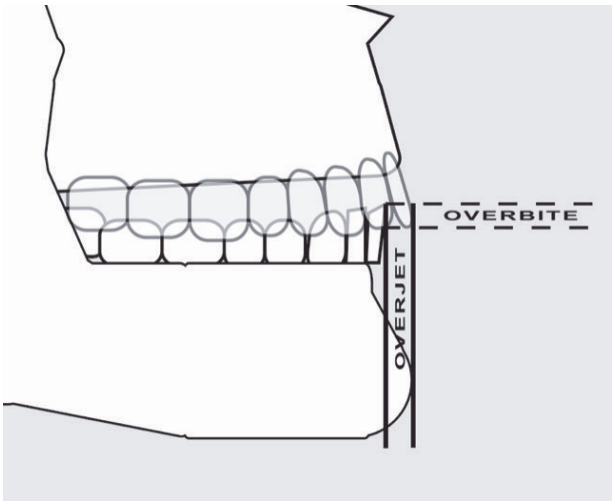

Figure 11. Overjet and overbite

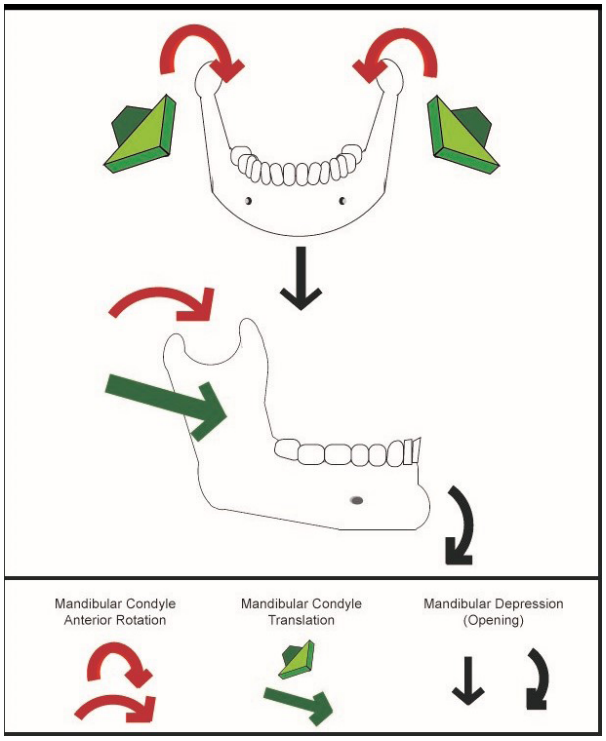

Figure 12. Mandibular depression (opening)

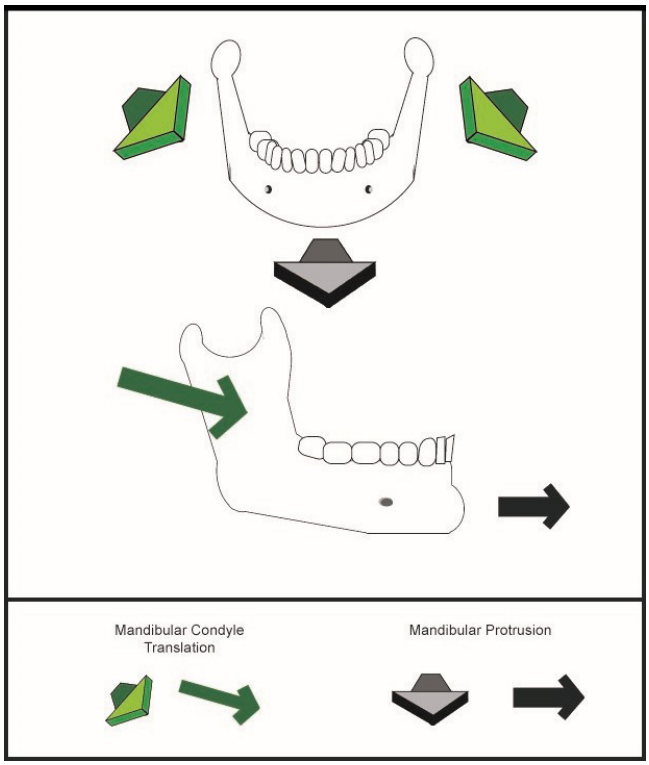

Figure 13. Mandibular protrusion

Vol. 31, No. 1. Printed in U.S.A.
1041-469X/$8.00/19

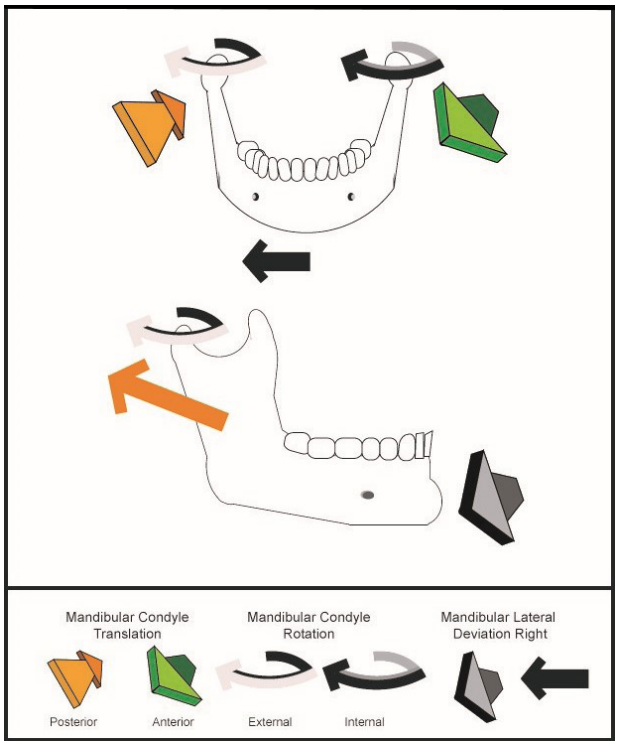

Figure 14. Right lateral deviation of the mandible

Mandibular Elevation (Closing)

The masseter, medial pterygoid and temporalis muscles are primarily responsible for mandibular elevation and subsequent bite force.[7,8] The lateral pterygoids engage on resistance to closing with the posterior temporalis helping to retract the condylar head.[7]

During closing, the ligaments and retrodiscal lamina pull the mandibular condyle and articular disc posteriorly returning them to their anatomical resting position.[8]

A study done by Merlini and Palla[17] showed there was a mostly linear relationship between opening angle and anterior translation in healthy opening and closing of the TM except in individuals with a larger mouth opening. This prompted a further study by Salaorni and Palla who examined the gait patterns of those with a normal TMJ and found that there were three types of opening patterns and four types of closing patterns that combined to give five basic groups of opening and closing.[15] A linear opening and closing pattern was still the most common, but only comprised 34% of the "gait" patterns. Clinically, this would support the observation of a variety of normal gait patterns as well as potential asymmetry side to side that may result in slight deviations during opening and closing.

Protrusion and Retrusion

Protrusion consists of bilateral anterior translation (forward and downward trajectory). The lateral pterygoids and medial pterygoids show the strongest activity during protrusion. There is also evidence of activity in the masseter, digastric, geniohyoid muscles and the middle fibres of temporalis.[7] (**See Figure 13**.) The study by Walker et al. reported a normal ROM in protrusion as 3 to 11 mm with a mean of 7.1 mm (± 2.3 mm).[16]

Retrusion consists of bilateral posterior translation (backward and upward trajectory). With retrusion, all parts of the temporalis muscle are active along with activity in the digastric and mylohyoid, to a lesser degree.[7]

Lateral Deviation

Lateral deviation has been described as ipsilateral lateral rotation (spinning) with contralateral anterior translation and medial rotation. It has also been found that there is posterior translation of the ipsilateral mandibular condyle.[18] On the ipsilateral side, the posterior fibers of temporalis, the digastric, mylohyoid and geniohyoid muscles act together contracting in unison. On the contralateral side, lateral and medial pterygoids are the prime movers in lateral deviation. There is also some activity in the middle fibers of temporalis, the digastric, mylohyoid and geniohyoid muscles.[7] (**See Figure 14**.) Walker et al. reported a normal ROM in lateral deviation (excursion) as 5 to 12 mm with a mean of 8.8 mm (± 2.1 mm) to the left and 5 to 14 mm with a mean of 9.6 mm (± 2.6 mm) to the right.[5]

REFERENCES

1. National Institutes of Health. National Institute of Dental and Craniofacial Research. TMJ Disorders. NIH Publication No. 06-3487. Bethesda, MD: National Institute of Dental and Craniofacial Research: 2006.
2. Stohler C. Masticatory myalgias. In: Oral and Maxillofacial Surgery. Temporomandibular Disorders. Edited by Fonseca RJ, et al.: Philadelphia: WB Saunders. 2000;38-45.
3. LeResche L. Epidemiology of temporomandibular disorders: implications for the investigation of etiologic factors. Crit Rev Oral Biol Med. 1997;8:291-305.
4. Gremillion H, Mahon P. The prevalence and etiology of temporomandibular disorders and orofacial pain. Texas Dental J. 2000;117:30-39.
5. Shiau YY, Kwan HW, Chang C. Prevalence of temporomandibular disorder syndrome (TMD) in university students: a third year report of the epidemiological study in Taiwan. Chin Dent J. 1989;8:106-116.
6. Tanaka E, Koolstra JH. Biomechanics of the temporomandibular joint. Journal of dental research. 2008 Nov;87(11):989-991.
7. Helland MM. Anatomy and function of the temporomandibular joint. Journal of Orthopaedic & Sports Physical Therapy. 1980 Jan 1;1(3):145-152.
8. Herb K, Cho S, Stiles MA. Temporomandibular joint pain and dysfunction. Current pain and headache reports. 2006 Nov 1;10(6):408-414.
9. Langendoen J, Müller J, Jull GA. Retrodiscal tissue of the temporomandibular joint: clinical anatomy and its role in diagnosis and treatment of arthropathies. Manual therapy. 1997 Nov 1;2(4):191-198.
10. Moore, KL. Clinically oriented anatomy. 2nd Edition. Baltimore: Williams & Wilkins, 1985.
11. Davidson JA, Metzinger SE, Tufaro AP, Dellon AL. Clinical implications of the innervation of the temporomandibular joint. Journal of Craniofacial Surgery. 2003 Mar 1;14(2):235-239.
12. Cuccia AM, Caradonna C, Caradonna D, et al. The arterial blood supply of the temporomandibular joint: an anatomical study and clin-

Vol. 31, No. 1. Printed in U.S.A.
1041-469X/$8.00/19

ical implications. Imaging science in dentistry. 2013 Mar 1;43(1):37-44.
13. Gallois R. Classification of Malocclusion. www.columbia.edu/itc/hs/dental/D5300/Classification%20of%20Malocclusion%20GALLOIS%2006%20final_BW.pdf. Accessed October 15, 2018.
14. Allanson JE, Cunniff C, Hoyme HE, et al. Elements of morphology: standard terminology for the head and face. American Journal of Medical Genetics Part A. 2009 Jan;149(1):6-28.
15. Salaorni CA, Palla S. Condylar rotation and anterior translation in healthy human temporomandibular joint. Schweiz Monatsschr Zahnmed. 1994;104:415.
16. Walker N, Bohannon RW, Cameron D. Discriminant validity of temporomandibular joint range of motion measurements obtained with a ruler. J Orthop Sports Phys Ther. 2000 Aug;30(8):484-492.
17. Merlini L, Palla S: The relationship between condylar rotation and anterior translation in healthy and clicking temporomandibular joints. Schweiz Monatsschr Zahnmed. 98:1191-1199.
18. Shaffer SM, Brismée JM, Sizer PS, Courtney CA. Temporomandibular disorders. Part 1: anatomy and examination/diagnosis. Journal of manual & manipulative therapy. 2014 Feb 1;22(1):2-12.

AUDIO LECTURES

Temporomandibular Dysfunction (TMD)

Justin Hildebrand, DC

Dr. Justin Hildebrand received his DC degree from Cleveland Chiropractic College (CCC) in 2010. He started KC North Spine and Joint Center in Kansas City, MO. Currently, Dr. Hildebrand is an adjunct professor at CCC, a speaker for NCMIC on musculoskeletal conditions, and treats athletes of all kinds in Kansas City. He is licensed to practice acupuncture and is certified in dry needling.

LECTURE I OUTLINE

I. Why Treat the Temporomandibular Joint?
II. Anatomy
  A. Joint
  B. Muscles
    i. masseter
    ii. temporalis
    iii. medial pterygoid
    iv. lateral pterygoid
    v. digastric
  C. Muscle referral patterns
  D. Biomechanics
  E. The disc
III. Clinical Signs of Temporomandibular Disorder
IV. Exam
  A. History considerations
  B. Co-morbid conditions
  C. Observe opening
    i. supine
    ii. seated
  D. Palpation
  E. Tests
    i. three finger test
    ii. centric relation
    iii. measuring opening
    iv. TMJ reflex
    v. cranial nerves
  F. Treatments
    i. passive
    ii. active
      1. trigger points
      2. myofascial release
      3. post-isometric relaxation
      4. rehab

REFERENCES

Hammer WI. Functional Soft-Tissue Examination and Treatment by Manual Methods. Sudbury, MA: Jones and Bartlett Publishers; 2007.
Lewit K. Manipulative Therapy: Musculoskeletal Medicine. London, England: Elsevier/Churchill Livingstone; 2010.
Magee DJ. Orthopedic Physical Assessment. Vancouver, Canada: Langara College; 2017.
Neumann DA. Kinesiology of the Musculoskeletal System: Foundations for Rehabilitation. Maryland Heights, MO: Mosby/Elsevier; 2010.
Otis CA. Kinesiology: The Mechanics & Pathomechanics of Human Movement. Philadelphia, PA: Lippincott Williams & Wilkins; 2009.
Simons DG, Travell JG, Simons LS, Cummings BD. Travell & Simons' Myofascial Pain and Dysfunction: the Trigger Point Manual. Philadelphia, PA: Lippincott Williams & Wilkins; 1999.

LECTURE II OUTLINE

Temporal Mandibular Dysfunction and Psychosocial Factors

Christopher Kinslow, DC, DPT

Dr. Chris Kinslow is an Assistant Professor at the University of Saint Mary in the Stefani Doctorate of Physical Therapy program, and he is the owner of Chiropractic Physical Therapy Corporation, an outpatient orthopaedic clinic located in Weston, MO. Dr. Kinslow's clinical expertise includes manual therapy, dry needling and skeletal manipulation. He is a certified orthopaedic specialist and holds both a level one and two Functional Dry Needling Certification. Dr. Kinslow has co-authored research articles on the effects of dry needling and spinal manipulative therapy.

Vol. 31, No. 1. Printed in U.S.A.
1041-469X/$8.00/19

LECTURE II OUTLINE

I. Introduction: TMD Prevalence
   A. Cost to society
   B. Cost to individuals
   C. Gender bias of TMD
II. Biopsychosocial vs. Biomechanical Model of Pain
   A. Research supporting biopsychosocial influences
   B. TMD and depression
   C. TMD and stress
   D. TMD and anxiety
   E. TMD and abuse
   F. TMD and catastrophizing
III. Using Pain Science to Address the Underlying Issues that May Be at the Root of TMD
   A. Better subjective questions
   B. Promote movement, reduce fear, multidisciplinary approach
   C. Educate patients about how pain works
   D. Sleep hygiene

REFERENCES

Alkhudhairy MW, Al Ramel F, Al Jader G, et al. A self-reported association between temporomandibular joint disorders, headaches, and stress. J Int Soc Prev Community Dent. 2018 Jul-Aug;8(4):371-380.

Armijo-Olivo S, Pitance L, Singh V, et al. Effectiveness of manual therapy and therapeutic exercise for temporomandibular disorders: systematic review and meta-analysis. Phys Ther. 2016 Jan;96(1):9-25.

Chow JC, Cioffi I. Effects of trait anxiety, somatosensory amplification, and facial pain on self-reported oral behaviors. Clin Oral Investig. 2018 Aug 27.

Dahlström, L. Conservative treatment of mandibular dysfunction. Clinical, experimental and electromyographic studies of biofeedback and occlusal appliances. Swed Dent J Suppl. 1984;24:1-45.

De La Torre Canales G, Câmara-Souza MB, Muñoz Lora VRM, et al. Prevalence of psychosocial impairment in temporomandibular disorder patients: a systematic review. J Oral Rehabil. 2018 Nov;45(11):881-889.

Diener I, Kargela M, Louw A. Listening is therapy: patient interviewing from a pain science perspective. Physiother Theory Pract. 2016 Jul;32(5):356-367.

Gil-Martínez A, Paris-Alemany A, López-de-Uralde-Villanueva I, La Touche R. Management of pain in patients with temporomandibular disorder (TMD): challenges and solutions. J Pain Res. 2018;11:571-587.

Grossi PK, Bueno CH, de Abreu Silva MÁ, et al. Evaluation of sexual, physical, and emotional abuse in women diagnosed with temporomandibular disorders: A case-control study. Int J Prosthodont. 2018 Nov-Dec;31(6):543-551.

Maixner W, Diatchenko L, Dubner R, et al. Orofacial pain prospective evaluation and risk assessment study–the OPPERA study. J Pain. 2011:12(11):T4-T11.

Natu VP, Yap AU, Su MH. Temporomandibular disorder symptoms and their association with quality of life, emotional states and sleep quality in South-East Asian youths. J Oral Rehabil. 2018 Oct;45(10):756-763.

Nazeri M, Ghahrechahi HR, Pourzare A, et al. Role of anxiety and depression in association with migraine and myofascial pain temporomandibular disorder. Indian J Dent Res. 2018 Sep-Oct;29(5):583-587.

Østensjø V, Moen K, Storesund T, Rosén A. Prevalence of painful temporomandibular disorders and correlation to lifestyle factors among adolescents in Norway. Pain Res Manag. 2017;2017:2164825.

Reiter S, Eli I, Mahameed M, Emodi-Perlman A, et al. Pain catastrophizing and pain persistence in temporomandibular disorder patients. J Oral Facial Pain Headache. 2018;32(3):309-320.

Slade GD. Epidemiology of temporomandibular joint disorders and related painful conditions. Molecular Pain. 2014;10(Suppl 1):O16.

Staniszewski K, Lygre H, Bifulco E, et al. Temporomandibular disorders related to stress and HPA-axis regulation. Pain Res Manag. 2018 May 2;2018:7020751.

Wozniak E, Loster JE, Wieczorek A. Relation between headache and mastication muscle tone in adolescents. Pain Res Manag. 2018 Sep 23;2018:7381973.

D.C. Tracts. Copyright © 2019 Data Trace Publishing Company
Vol. 31, No. 1. Printed in U.S.A.
1041-469X/$8.00/19

JURIS-PROOFING

Brian J. Gleberzon, DC

Dr. Brian J. Gleberzon graduated from the Canadian Memorial Chiropractic College in 1989. After entering private practice in Toronto, Ontario he began teaching at CMCC in 1994. He currently holds the rank of Professor and Departmental Chair. Dr. Gleberzon teaches technique and clinical education and is the coordinator of the Healthy Ageing and the Jurisprudence, Ethics and Business Management courses. He served nine years on the College of Chiropractors of Ontario and is currently on the Board of Directors of the Ontario Chiropractic Association. He has authored two textbooks, several textbook chapters and over 60 journal articles in peer-reviewed journals. He has presented at national and international conferences and received the Research of the Year Award in 2001 and the Professional Services Award in 2008. Dr. Gleberzon is currently pursuing his PhD from the University of South Wales, UK.

INTRODUCING *JURIS-PROOFING*

Welcome to the inaugural edition of *Juris-Proofing*, a new segment of *D.C. Tracts* which will offer a risk management-related article in each issue for the chiropractor in private practice. The author, Brian J. Gleberzon, DC, is a frequent contributor to *D.C. Tracts* with a great deal of experience in risk management.

What is juris-proofing? The answer is simple. We are all familiar with the concept of safety-proofing a home for a small child. Electrical sockets are covered, table corners are cushioned and toxic substances are placed out of reach. In other words, we know that the best way to manage an injury to a child is to prevent it from happening in the first place.

In much the same way, the emphasis of these articles will be to provide strategies to avoid a patient launching a complaint to the regulatory body in the jurisdiction in which you practice, or (more

realistically) to help you fortify your practice in the event that a complaint is launched and you are required to defend yourself. I consider this scenario more realistic because *anyone* can launch a complaint against you at any time, even if it is completely without merit.

The person who taught me jurisprudence when I was a chiropractic student was fond of saying two things when it came to patient complaints: one was, "if you don't have a complaint launched against you during your professional career you're not seeing enough patients," and the other, "if you never have a complaint launched against you, you you're either lucky or you're smart, and nobody is that smart."

Future articles will provide a glimpse into complaint and discipline processes, and will provide strategies to juris-proof your patient interview, physical examination, report of findings and care planning. I will specifically focus on what are the most common causes of complaints, explain how to obtain informed consent from your patient and how to juris-proof your patient health records. I'll also explain what to do in the event that you find yourself the subject of a complaint or negligence claim.

But first, two fundamental questions have to be answered: A) Why should you listen to me, and B) Why should you care at all?

Why listen to me?

It is reasonable for you to wonder why you should take my advice. After all, I'm not a healthcare lawyer and I've never attended a single day of law school in my life.

By way of experience, in 2004 I became a consultant for the regulatory body in Ontario, Canada, the College of Chiropractors of Ontario (CCO). In 2007, I was elected to the CCO Council. I served for nine years on that council — the maximum time allowed.

While on CCO, I served on all of its committees including Executive, Complaints, Quality Assurance, Patient Relations, Fitness to Practice and Registration and Advertising, often serving as Committee Chair. I was also a panelist for several Discipline Hearings. Although I served on these committees for only one or two-year terms, I served on the Inquiries, Reports and Complaints Committee for all nine years, four of those years as Chair. Since the ICRC typically reviewed 100 cases per year, I was involved in the adjudication of almost 900 cases alleging professional misconduct against members.

I have also taught the Jurisprudence, Ethics and Business Management course at the Canadian Memorial Chiropractic College since 2008, and I've published two textbooks, a technique manual and over 60 articles in peer-reviewed journals

In 2016 I was elected to the Ontario Chiropractic Association, the largest advocacy organization in Canada. I also currently maintain a private practice. Taken together, to paraphrase a current ad for a particular insurance company: *"I know a thing or two because I've seen a thing or two"*

D.C. Tracts. Copyright © 2019 Data Trace Publishing Company
Vol. 31, No. 1. Printed in U.S.A.
1041-469X/$8.00/19

Why should you care?

I'm often amazed when reading the reasons why a member has had their license suspended or revoked, as it is often abundantly clear that they didn't consider the ramifications and collateral damage that a suspended license will bring.

First, the complaints investigation itself is costly, both in terms of time and money, even if your malpractice provider will cover your initial legal costs. You have to gather all the information requested by the Complaints Committee or by an appointed investigator, who often presents with a subpoena and can seize any documents they deem relevant to the investigation. The investigation by the Complaints Committee can take several months to complete, and is it very anxiety-inducing, even if you did nothing wrong.

If your case is referred to discipline, you typically have to carry all legal costs yourself, which can quickly reach tens of thousands of dollars.

If you're found guilty, part of the penalty is a reprimand by the Discipline Panel, in open court, which means that members of the public can witness you being humiliated by your peers. The Discipline Panel can order you to pay for part of the hearing, which can reach tens or even hundreds of thousands of dollars. The Panel hands down their decision, dictating for what length of time your license will be suspended. This is when things get really bad.

Imagine having to inform your spouse, your children, your parents, your grandparents and your friends that you are not allowed to practice chiropractic in any capacity whatsoever for the length of your suspension. Furthermore, since discipline decisions are posted on a regulatory body's website, anyone can search your name and discover not only that you are suspended, but also the reason why.

You may have to shut down your practice. Even if you tell your patients you're "going on a vacation" or "have a health issue you have to manage," they can easily find out the truth with a simple Google search. Moreover, some jurisdictions require you post the discipline decision on your office door, for all the world to see.

It goes without saying that your business and personal costs are not halted just because your license to practice is suspended. You still have to make rent payments, pay staff, handle operating costs and continue to service other debts (home mortgage, car payments, student loans, credit card debts and so on).

If you hire a locum or ask your associate to treat your patients while you're under suspension, they will typically keep half of all revenue collected.

Even once you are reinstated, the discipline decision permanently remains on the regulatory body's public registry, forever viewable by everyone, including prospective patients and employers.

Third-party payers (insurance companies, Medicaid, Medicare, etc.) may blackball you, meaning they will not accept invoices you directly submit on behalf of your patients. It is also conceivable that they may not reimburse your patients if they submit an invoice directly to them once they discover that you were the chiropractor rendering care.

I hasten to add that American chiropractors found guilty of defrauding Medicaid or Medicare by Discipline Panels are often charged civilly, since they are technically defrauding the United States government. Not only do they have to repay the money they

took, additional penalties include fines totalling thousands of dollars and even jail time.

The last thing to consider is this: How will this affect your legacy? It seems that too many chiropractors do not think about this at all. After all, the only thing you leave behind in this world is your reputation, and a disciplinary consequence can leave on it an indelible blemish.

The next issue of Juris-Proofing will review the most common causes of complaints and the decision-making process that results in allegations of these complaints being referred to Discipline.

ABSTRACTS AND COMMENTARIES

Yasmeen A. Khan, DC, MS

INTRODUCTION

Temporomandibular joint pain and muscle disorders (TMJDs) are some of the most commonly-occurring chronic musculoskeletal conditions resulting in pain and disability, second only to chronic low back pain.[1] TMJDs affect approximately 5 to 12% of the worldwide population, with approximately 15% developing chronic TMJD.[1] The annual cost of this condition is estimated at $4 billion with one-half to two-thirds of those with TMJDs seeking treatment.[1] Interestingly, unlike other chronic health conditions, TMJDs are more common in younger populations.[1] TMJDs are also approximately twice as prevalent in women compared to men.

A substantial proportion of chiropractic clinicians may indicate treating patients who report TMJDs, although the prevalence of this condition in chiropractic settings is unclear. Nearly 34 million (14%) people in the US seek chiropractic care each year.[2] It is likely that a large percentage of those seeking care for neck pain and headaches may also report symptoms of TMJD, as illustrated in the articles discussed below.

As the second most common chronic musculoskeletal condition, the topic of TMJDs may be clinically pertinent to many readers. TMJDs have proven challenging to treat across many disciplines, with studies conducted in chiropractic settings indicating mixed results regarding the efficacy of manipulation for its treatment.[3] Nevertheless, TMJDs will continue to exist and be treated by many chiropractic clinicians, necessitating further study.

The articles below demonstrate results from studies related to TMJDs. One article is a case study of a 24-year-old female who received favorable results after a course of chiropractic care for TMJD.[4] Another describes favorable results achieved after five weeks of low-velocity mobilizations and cervical retraining exercises.[5] Though these results were obtained within a physiotherapy setting, similar procedures can be (and are) implemented in chiropractic settings. The commentaries end with a description of a literature review conducted by physiotherapy clinicians.[6] Overall, recent literature conducted in patient cohorts seeking chiropractic care for TMJDs is sparse. This indicates a need for future research efforts to describe whether specific chiropractic interventions affect patient outcomes.

REFERENCES

1. National Institute of Dental and Craniofacial Research. Facial pain. https://www.nidcr.nih.gov/research/data-statistics/facial-pain. Accessed Nov 21, 2018.
2. Gallup, Inc. Palmer College of Chiropractic Inaugural Report: Americans' Perceptions of Chiropractic. 2015. https://www.palmer.edu/alumni/research-publications/gallup-report/five-facts-about-chiropractic/. Accessed Nov 21, 2018.
3. DeVocht JW, Goertz CM, Hondras MA, Long CR, Schaeffer W, Thomann L, et al. A pilot study of a chiropractic intervention for management of chronic myofascial temporomandibular disorder. The Journal of the American Dental Association. 2013 Oct 1;144(10):1154–1163.
4. Jaeger JO, Oakley PA, Moore RR, et al. Resolution of temporomandibular joint dysfunction (TMJD) by correcting a lateral head translation posture following previous failed traditional chiropractic therapy: A CBP case report. J Phys Ther Sci. 2018 Jan;30(1):103-107.
5. Calixtre LB, Oliveira AB, de Sena Rosa LR, et al. Effectiveness of mobilisation of the upper cervical region and craniocervical flexor training on orofacial pain, mandibular function and headache in women with TMD. A randomised, controlled trial. J Oral Rehabil. 2019 Feb;46(2):109-119.
6. Butts R, Dunning J, Pavkovich R, et al. Conservative management of temporomandibular dysfunction: a literature review with implications for clinical practice guidelines (narrative review part 2). J Bodyw Mov Ther. 2017 Jul;21(3):541-548.

Resolution of Temporomandibular Joint Dysfunction (TMJD) by Correcting a Lateral Head Translation Posture following Previous Failed Traditional Chiropractic Therapy: A CBP Case Report

Jaeger JO, Oakley PA, Moore RR, Ruggeroli EP and Harrison DE. J Phys Ther Sci. 2018 Jan;30(1):103-107.

ABSTRACT

Purpose—To present the case of the resolution of right temporomandibular joint dysfunction (TMJD) following the correction of a right lateral head translation posture.

Methods—A 24-year-old female reported facial pain and jaw clicking in the right TMJ. Radiography revealed a 19-mm right head (shift) translation posture. TMJ vibration analysis showed characteristic abnormalities for the right TMJ. The patient was treated with CBP® technique mirror image left-sided exercises and traction methods, as well as spinal manipulative therapy (SMT).

Results—After 36 treatments over a 12-week period, a complete correction of the lateral head posture was achieved corresponding with a complete resolution of jaw pain and clicking. TMJ vibration analysis demonstrated normal right-side TMJ characteristics following treatment.

Conclusion—Abnormal head/neck postures (such as lateral head translation) may be an unrealized source of TMJD and may be explained through the "regional interdependence" model or by how seemingly unrelated anatomy may be associated with a primary complaint.

COMMENTARY

This case report was published by four chiropractic clinicians and a writer from the CPB institute (Chiropractic Biophysics, Inc). CBP is a chiropractic approach that was invented in the 1980s and incorporates exercises, spinal manipulative therapy and traction methods to restore spinal alignment and correct postures (e.g., lateral cervical deviation, loss of cervical lordosis).

The title of this particular article is perhaps slightly pejorative ("Previous Failed Traditional Chiropractic"), and does not account for possible positive outcomes received in the patient's previous experiences with chiropractic. However, the article presents a compelling case for looking beyond the temporomandibular joint (TMJ) in addressing TMJD symptoms. Authors specifically describe the relationship between cervical spinal alignment and posture and TMJ function. The clinicians collaborated with the patient's dentist, who employed TMJ vibration analysis to determine the side of TMJD involvement. The basis for this analysis was that friction and vibration are associated with mechanical displacements of the TMJ.

Clinicians provided approximately three CBP sessions per week over a three-month time period. Treatments included a left-sided head translation, a tilt traction maneuver and spinal manipulation, consistent with a standard CBP interventional protocol. The traction maneuver was employed for 15 minutes each session, in a seated or side-lying position depending on treatment phase. All procedures were delivered in-office and images of the traction interventions are provided in the manuscript.

This visit frequency may not be realistic for all patients or clinicians, depending on many factors. However, results of this case report are clinically significant. The lateral cervical deviation changed from 19 mm to 1.3 mm, and the patient's pain and annoyance decreased substantially (measured using the General Pain Index Questionnaire and the Neck Disability Index). According to the Neck Disability Index assessment, the patient's chronic TMJ pain and clicking was nearly gone, bothering her only very rarely. This article demonstrates that modifying cervical postural irregularities may be related to improved TMJD. Further clinical trials are needed to determine the extent of that relationship and whether clinicians can infer that altering cervical posture decreases TMJD symptoms.

The TMJ and its neighboring regions are rich with anatomy (such as cervical muscles, facial muscles, neurology and cranial joints), indicating that not all TMJDs originate in the TMJ itself. Addressing other contributing factors, as seen in this article, may be a key to achieving optimal results. With the patient's best interest in mind, addressing these factors or identifying appropriate referral routes may be a key component of care for patients experiencing TMJDs. This study may provide important preliminary data for larger-scale clinical trials. However, as a case report, results must be interpreted with caution and cannot be generalized to all patients receiving chiropractic care in general, or CBT in particular.

D.C. Tracts. Copyright © 2019 Data Trace Publishing Company
Vol. 31, No. 1. Printed in U.S.A.
1041-469X/$8.00/19

Effectiveness of Mobilization of the Upper Cervical Region and Craniocervical Flexor Training on Orofacial Pain, Mandibular Function and Headache in Women with TMD. A Randomized, Controlled Trial

Calixtre LB, Oliveira AB, de Sena Rosa LR, Armijo-Olivo S, Visscher CM and Alburquerque-Sendín F. J Oral Rehabil. 2019 Feb;46(2):109-119.

ABSTRACT

Background—Studies exploring interventions targeting the cervical spine to improve symptoms in patients with temporomandibular disorders (TMDs) are limited.

Objectives—To determine whether mobilization of the upper cervical region and craniocervical flexor training decreased orofacial pain, increased mandibular function and pressure pain thresholds (PPTs) of the masticatory muscles and decreased headache impact in women with TMD when compared to no intervention.

Methods—In a single-blind randomized controlled trial, 61 women with TMD were randomized into an intervention group (IG) and a control group (CG). The IG received upper cervical mobilizations and neck motor control and stabilization exercises for five weeks. The CG received no treatment. Outcomes were collected by a blind rater at baseline and at a five-week follow-up. Orofacial pain intensity was collected once a week. A mixed ANOVA and Cohen's *d* were used to determine differences within/between groups and effect sizes.

Results—Pain intensity showed significant time-by-group interaction ($p < 0.05$), with significant between-group differences at four and five weeks ($p < 0.05$), with large effect sizes ($d > 0.8$). The decrease in orofacial pain over time was clinically relevant only in the IG. Change in headache impact was significantly different between groups, and the IG showed a clinically relevant decrease after the treatment. No effects were found for PPT or mandibular function.

Conclusion—Women with TMD reported a significant decrease in orofacial pain and headache impact after five weeks of treatment aimed at the upper cervical spine compared to the CG.

COMMENTARY

This article was published by a team of scientists from Brazil, Canada, the Netherlands and Spain. The authors indicate that approximately 70% of persons who experience headaches also present with symptoms of TMJD. Furthermore, those with TMJD report a greater degree of headache-related disability than those experiencing headaches alone. Therefore, similar to the Jaeger et al. article described above, authors describe the interconnectedness between the TMJ and its surrounding structures.

This study was conducted using physiotherapy mobilizations and exercises, and results were obtained from a sample of women living in Brazil. It is unclear whether similar results would be found in a US population of people seeking chiropractic care. However, some US chiropractors may deliver similar courses of care to those described in this study. Participants who were randomized to the intervention group received ten sessions over five weeks, with a minimum of 48 hours between sessions. The control group did not receive any care from the study team during the five-week data collection time frame. It is possible that results are biased because participants were not blinded to their treatment group and placebo effects may have affected results. Nevertheless, the cervical manual interventions showed a statistically significant improvement over the control intervention within four weeks of the onset of care.

The intervention is worth mentioning. It included non-manipulative manual techniques and cervical motor control/stabilization exercises with biofeedback. Images of these techniques and descriptions about how they were delivered are located within the manuscript (**Figure 1**). Based on my clinical experience, they appear similar to low-force, non-thrust cervical interventions used in US chiropractic offices. Such interventions may be taught at chiropractic colleges or continuing education seminars. Clinicians may wish to augment their skills regarding the application of low-force techniques to address TMJDs and concomitant headaches.

It bears repeating that results were obtained from an all-female cohort. Though not explicitly stated, this study was likely conduced with females because TMJ and headaches are more common in women than men. Thus, research efforts were tailored to the population most in need of improved interventions. It is unclear how results may have differed if the cohort included persons of other genders. Overall, results indicate a benefit of low-force, manual, upper cervical techniques and motor retraining. Further investigation is needed to explore these phenomena in US chiropractic settings.

D.C. Tracts. Copyright © 2019 Data Trace Publishing Company
Vol. 31, No. 1. Printed in U.S.A.
1041-469X/$8.00/19

Conservative Management of Temporomandibular Dysfunction: A Literature Review with Implications for Clinical Practice Guidelines (Narrative Review Part 2)

Butts R, Dunning J, Pavkovich R, Mettille J and Mourad F. J Bodyw Mov Ther. 2017 Jul;21(3):541-548.

ABSTRACT

The effective management of temporomandibular dysfunction (TMD) requires a thorough understanding of the pathoanatomic factors that drive the underlying condition. After reviewing the etiology associated with TMD in Part 1 of this narrative review, the temporomandibular joint capsule, articular disc and muscles of mastication emerged as key players.

Part 2 focuses on conservative treatment strategies best able to reduce the pain and disability associated with TMD. A review of the literature revealed limited support of strengthening exercises targeting the muscles of mastication. There was also limited evidence for manual soft tissue work targeting muscles of mastication, which may be specifically related to the limited accessibility of the pterygoid muscles to palpation. For the reduction of pain, there was little to no evidence supporting splint therapy and electrophysical modalities, including laser therapy, ultrasound, TENs and iontophoresis. However, for the reduction of pain and disability, non-thrust mobilization and high-velocity, low-amplitude thrust manipulation techniques to the TMJ and/or upper cervical articulations that directly and indirectly target the TMJ joint capsule were generally supported in the literature.

Studies that used dry needling or acupuncture of the lateral pterygoid and posterior, peri-articular connective tissue also led to significant improvements in pain and disability in patients with TMD. Thus, the most effective conservative management of TMD seems to be techniques best able to impact anatomic structures directly related to the etiology of TMD, to include the joint capsule, articular disc and muscles of mastication, specifically the superior and inferior head of the lateral pterygoid.

COMMENTARY

Defining the practice of chiropractic is challenging, and there is wide diversity in the application of the science, art and philosophy of chiropractic worldwide. While some clinicians employ spinal manipulative therapy alone, many employ physiotherapy modalities, motor rehabilitation, acupuncture and myotherapies in lieu of (or in conjunction with) spinal manipulation. Therefore, remaining informed of the literature base regarding the use of non-invasive therapies is paramount.

This literature review is an assessment of the current state of literature regarding conservative care for the treatment of TMJD. Similar to the other articles mentioned in this issue, authors describe the importance of treating the anatomical structures consistent with TMJD, such as the muscles of mastication, the joint capsule (TMJ) itself and the cervical spine.

A limitation of the article is that it does not indicate a strong rationale for conducting the review, nor does it state the methods

authors used in obtaining articles. In other words, this is not a methodologically rigorous literature review. However, it contains an organized list of categories (such as "temporomandibular dysfunction and exercise," "temporomandibular dysfunction and soft tissue release") with corresponding descriptions of relevant studies, as assessed by the authors. This may be an article of interest for busy clinicians looking for a summary of literature related to the following TMJD treatments: exercises for mastication muscles, soft tissue release, electrophysical modalities, splint therapy, joint mobilization, joint mobilization and/or manipulation, and needling modalities (such as acupuncture).

It is worth noting that some articles related to manipulation for TMJD appear to be missing from their literature review.[1] As mentioned, it is unclear how articles were selected for inclusion. Authors note that manipulation of the cervical spine and TMJ are effective in the treatment of TMJDs, yet this conclusion differs from those drawn in previously published articles.[1] Overall, this article provides a snapshot of a variety of articles pertinent to treating TMJDs with non-invasive therapies. It may be prudent for readers to use this article as a springboard into further literature searches, specifically looking for clinical trials and systematic reviews regarding the topics covered within the article.

REFERENCE

1. DeVocht JW, Goertz CM, Hondras MA, et al. A pilot study of a chiropractic intervention for management of chronic myofascial temporomandibular disorder. The Journal of the American Dental Association. 2013 Oct 1;144(10):1154-1163.

D.C. Tracts (ISSN #1041-469X) is published quarterly; one volume per year, by Data Trace Publishing Company, P.O. Box 1239, Brooklandville, MD 21022.

The facts, opinions and views expressed in the lectures and printed information in *D.C. Tracts* are those exclusively of the participant and not those of Data Trace Publishing Company, which disclaims any liability or responsibility therefore.

Subscription Rates: The regular subscription price for Volume 31 (2019) is $229.00. The library and institutional rate is $259.00. Outside the U.S. add $80.00 for foreign subscriptions and $25.00 for Canadian subscriptions. (Rates are subject to change without notice.)

To Order: New subscriptions are entered to begin with the Spring (#1) issue. Orders should be mailed to: Data Trace Publishing Company, P.O. Box 1239, Brooklandville, MD 21022-1239. Subscribers may call **TOLL FREE 800-342-0454** to place an order or call **410-494-4994** outside the U.S. Fax: **410-494-0515.** Checks should be made payable to Data Trace Publishing Company. Visa, Mastercard, and American Express orders are also accepted.

Editorial Correspondence: Editorial correspondence should be sent to: Bryan M. Bond, 4100 S. 4th St., Leavenworth, KS 66062.

www.datatrace.com

CONTINUING EDUCATION QUESTIONNAIRE

The *D.C. Tracts* Continuing Education (CE) program is intended to be a 24-credit-per-year program. Each issue will have 20 Board Examination quality multiple-choice questions, and these will be published in each of the four *D.C. Tracts* quarterly issues. Subscribers will receive a maximum of 6 credit hours per issue for each correctly completed and submitted CE Answer Form. All applicants for credit must be *D.C. Tracts* subscribers or multiple-use subscribers. Participants must pass (70% correct) the written examination material in order to receive credit, but may request one retake of any issue for which they did not initally receive credit. The fee for a retake is $10.00 per test. *D.C. Tracts* will issue certificates to participants. It is the doctor's responsibility to send certificates to state boards.

Credit for the *D.C. Tracts* Continuing Education program is sponsored by the Logan University College of Chiropractic. Visit http://www.datatrace.com/medical/dc_cme_credits.htm to see how many credits your state's board accepts.

INSTRUCTIONS: The following questions are based on the material presented in the journal issue and on the accompanying lecture CD. Please select the best answer and mark the appropriate box on the CE Answer Form in this issue.

Answer Forms can be:

Faxed: 410-494-0515
Emailed: info@datatrace.com
Mailed: Continuing Education Director
Data Trace Publishing Company
PO Box 1239
Brooklandville, MD 21022

FEATURE ARTICLE QUESTIONS

1. What four muscles are considered the muscles of mastication?
   A. Buccinator, digastric, medial pterygoid, masseter
   B. Omohyoid, lateral pterygoid, temporalis, mylohyoid
   C. Medial pterygoid, lateral pterygoid, masseter, temporalis
   D. Masseter, digastric, mylohyoid, buccinator

2. In the face, the coronoid process is part of which bone, and serves as an attachment of which muscle?
   A. Maxilla; buccinator
   B. Mandible; temporalis
   C. Sphenoid; temporalis
   D. Temporal; medial pterygoid

3. During normal mandibular depression (opening), which is the main muscle responsible for initiating and continuing this action?
   A. Lateral pterygoid
   B. Temporalis
   C. Buccinator
   D. Omohyoid

LECTURE I QUESTIONS

4. Which muscle is NOT a muscle of mastication?
   A. Temporalis
   B. Masseter
   C. Medial pterygoid
   D. Sternocleidomastoid

5. Which muscle divides into two sections and connects the zygomatic arch to the mandible?
   A. Temporalis
   B. Masseter
   C. Medial pterygoid
   D. Lateral pterygoid

6. Which muscle of mastication refers pain from the cheek to the TMJ?
   A. Temporalis
   B. Masseter
   C. Medial pterygoid
   D. Lateral pterygoid

7. In the first 25 degrees of opening the mouth, the mandibular condyles rotate _____ and translate _____.
   A. posteriorly; inferiorly and laterally
   B. anteriorly; inferiorly and laterally
   C. posteriorly; superiorly and laterally
   D. anteriorly; inferiorly and medially

8. Which of the following is NOT descriptive of the TMJ disc?
   A. Bi-concave
   B. Thicker anteriorly and posteriorly
   C. Surrounded by ligaments for alignment
   D. Thicker in the middle

9. Which positive TMD test or screen suggests that co-management may be necessary?
   A. Abnormal three-finger/two-knuckle test
   B. Centric relation provocation test
   C. Palpable jaw clicking
   D. Active trigger points

10. In a dysfunctional movement cycle, overactive masseters can lead to inhibition of which muscles?
    A. Suprahyoid muscles
    B. Lateral pterygoids
    C. Temporalis
    D. Medial pterygoids

LECTURE II QUESTIONS

11. Different sources listed the incidence of TMD in our population as being in which of the following ranges?
    A. 3% - 12%
    B. 8% - 20%
    C. 10% - 30%
    D. 50% - 80%

12. TMD is more common in which population?
    A. Females
    B. Individuals who regularly exercise
    C. Urban areas
    D. Two-parent households

13. In what part of the biopsychosocial model of pain would a patient's education level fall?
    A. Biological
    B. Psychological
    C. Social
    D. Biomechanical

14. Somatization is commonly seen in TMD patients. Which of the following is the best definition of somatization?
    A. Popping of the TMJ with opening but not closing
    B. Overactivity of the temporalis and masseter muscle groups
    C. Recurrent and multiple medical symptoms without organic cause
    D. Overbite in dentation with clicking

15. Which postural alteration was linked to TMD?
    A. Forward shoulders
    B. Hyperlordosis of the cervical spine
    C. Hyperlordosis of the lumbar spine
    D. Genu varum

16. Which of the following best explains TMD pain?
    A. Pain signal goes from the TMJ to the brain
    B. Pain fibers connect the TMJ to the brain
    C. TMD pain is modulated at many points.
    D. TMD pain is unmodulated by areas other than the brain.

17. Sleep hygiene is a factor that impacts TMD. Which of the following is a recommendation for better sleep hygiene?
    A. Turn off all electronic devices at least five hours prior to bed.
    B. Drink caffeine late at night.
    C. Drink alcohol late at night.
    D. Lower the thermostat at bedtime.

ABSTRACTS/COMMENTARIES QUESTIONS

18. Jaeger et al. would suggest that which of the clinical features may be related to TMJD?
    A. Torticollis and headache
    B. Lateral head translation and TMJ clicking
    C. History of neck trauma
    D. Scoliosis and thoracic back pain

19. According to Calixtre et al., which may be an effective treatment for women experiencing headaches and TMJD?
    A. Home strengthening exercises
    B. Physiotherapy modalities
    C. Upper cervical mobilization and motor exercises
    D. Motor exercises alone

20. Butts et al. indicate substantial literature supporting the efficacy of _____ in decreasing TMJD-related pain and disability.
    A. manipulation of cervical spine and TMJ
    B. splint therapy
    C. electrotherapy modalities
    D. manual therapy to musculature